

Clinical anatomy for airway management and vascular access

Dr.K.Ashok

*Consultant Cardiac Anesthetist,
SRM Medical college Hospital, Chennai.*

AIRWAY ANATOMY: IT'S IMPORTANCE

A clear mental picture or “gestalt” of upper airway anatomy is an essential cognitive underpinning to airway management skills. This knowledge is important for the following reasons.

1. **Making decisions:** Assessment of a patient’s airway anatomy is the foundation upon which the airway plan is built. Based on this assessment, the clinician can decide how to proceed: with a rapid-sequence intubation, an awake intubation, or primary surgical airway.
2. **Structure and function:** Knowledge of airway anatomy and its dynamic changes facilitates the appropriate performance of airway opening skills and bag-mask ventilation. These skills depend on an understanding of functional airway anatomy and how the tissues behave with the patient in either the awake or obtunded state.
3. **Landmark recognition:** A sound three-dimensional appreciation of the laryngeal inlet and its surroundings is critical for optimal laryngoscopy. Anatomic structures adjacent to the glottic opening, such as the epiglottis and paired posterior cartilages help provide a “roadmap” to the cords.
4. **Spatial orientation:** Particularly when using blind or indirect visual intubation techniques, a clear mental image of the anatomy through which the instrument is travelling is required.

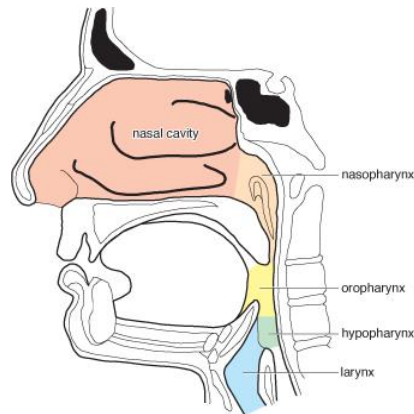
FUNCTIONAL AIRWAY ANATOMY

THE UPPER AIRWAY

The upper airway may be defined as the space extending from the nose and mouth down to the cricoid cartilage, while the lower airway refers to the tracheobronchial tree.

THE NASAL CAVITY

During normal breathing in the awake state, inspired air travels through, and is humidified by, the nasal cavity. The nasal cavity is bounded laterally by a bony framework which included the three turbinates (conchae) and medially by the bony septum.



The Upper airway anatomy

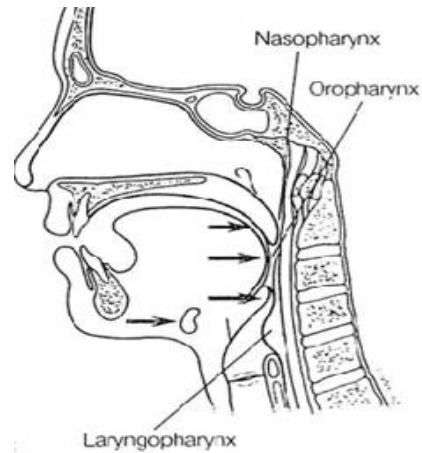
Septal deviation occurs commonly, and can impede passage of a nasal endotracheal (ET) tube, as can a hypertrophied inferior turbinate. The space between the inferior turbinate and the floor of the nasal cavity, termed the “**major nasal airway**”, is oriented slightly downward. During an attempted nasal intubation, the ET tube should therefore be directed straight back and slightly inferiorly. This will help traverse the widest aspect of the nasal airway, beneath the inferior turbinate, while avoiding the thin bone of the more superiorly located cribriform plate. The nasal cavity is well vascularised, particularly at the anterior inferior aspect of the nasal septum. Many authorities espouse directing an ET tube bevel toward the septum to minimize the potential for bleeding caused by traumatizing the vascular Kiesselbach’s plexus.

THE NASO- AND OROPHARYNX AND THE MANDIBLE

The nasal cavity terminates posteriorly at the level of the end of the nasal septum. The space from here to the tip of the soft palate is referred to as the nasopharynx. The oropharynx extends backward from the palatoglossal fold down to the epiglottis.

The oro- and nasopharynx are common sites of narrowing or complete airway obstruction in the obtunded patient, as the loss of tone in muscles responsible for maintenance of airway patency allows for posterior movement of soft palate, tongue, and epiglottis. In the obtunded patient, significant airway narrowing or obstruction can occur in one or all of the three locations.

- In the **nasopharynx**, as the soft palate meets the posterior pharyngeal wall (PPW).
- In the **oropharynx**, as the tongue moves posteriorly to lie against the soft palate and PPW
- In the **laryngopharynx**, as the epiglottis moves posteriorly towards the PPW.



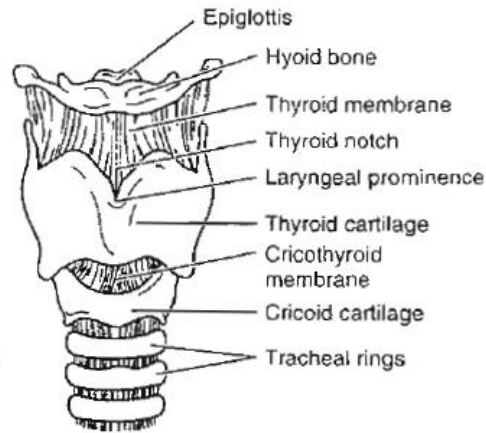
The **mandible** figures prominently in alleviating functional airway obstruction. The horse-shoe-shaped mandible extends superiorly via two rami to end in the coronoid process and condylar head. The condylar head in turn articulates with the temporal bone at the temporo-mandibular joint (TMJ), and allows for mouth opening by rotation. In addition, anterior translation of the condyle at the TMJ permits forward movement of the mandible. This is crucial for two reasons:

- As the inferior aspect of the tongue is attached to the mandible, anterior translation of the jaw elevates the tongue away from the posterior pharyngeal wall, helping to attain a clear airway in the obtunded patient.
- During laryngoscopy, the laryngoscope blade moves the mandible forward, helping to displace the tongue anteriorly and away from obstructing the line-of-sight view of the laryngeal inlet.

In addition to forward movement of the mandible and tongue, a laryngoscope blade also seeks to displace the tongue into the bony framework of the mandible: this is why individuals with small mandibles (receding chins), present difficulty with laryngoscopy.

THE LARYNGOPHARYNX

The laryngopharynx extends from the epiglottis down to the inferior border of the cricoid cartilage. On either side of the larynx, are the **piriform recesses**, while the esophagus is located posteriorly. The larynx, which sits at the entrance to the trachea opposite the C4-C6 vertebrae, is a complex structure consisting of multiple articulating cartilages, ligaments and muscles. The cartilages involved are the cricoid, thyroid, and epiglottis, together with the smaller paired arytenoid, corniculate and cuneiform cartilages.



Larynx - anterior view

Located anteriorly in the midline, the shield-shaped **thyroid cartilage** is attached by the thyrohyoid membrane to the hyoid bone above, and articulates inferiorly with the cricoid cartilage. The cricoid cartilage is a circular, signet-ring-shaped cartilage which marks the lower border of the laryngeal structure.

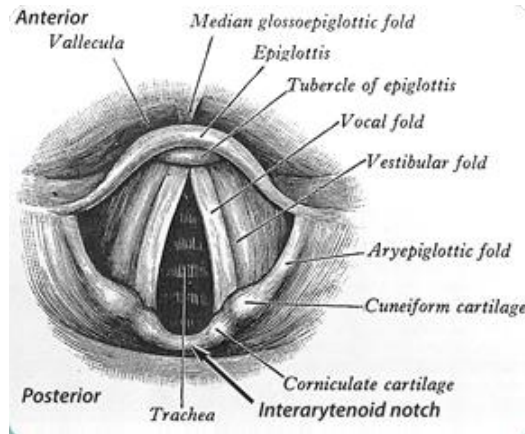
The **cricoid cartilage** is significant in airway management for a number of reasons:

- The Sellick maneuver or rearward dislocation of the larynx is produced by continuous pressure on the cricoid cartilage. This pressure performs a dual function, first the movement backwards of the larynx allows visualization of the vocal chords and eases the passage of the ET tube, and, second, this pressure obstructs the esophagus (an effect which has not been sufficiently demonstrated), preventing reflux of the contents of the stomach to the oropharynx.
- It is the narrowest point of the airway in the pediatric patient (the glottic opening is narrowest in the adult patient).
- The cricoid cartilage, together with the thyroid cartilage, is a landmark for locating the cricothyroid membrane, an area of critical importance in performing an emergency surgical airway.

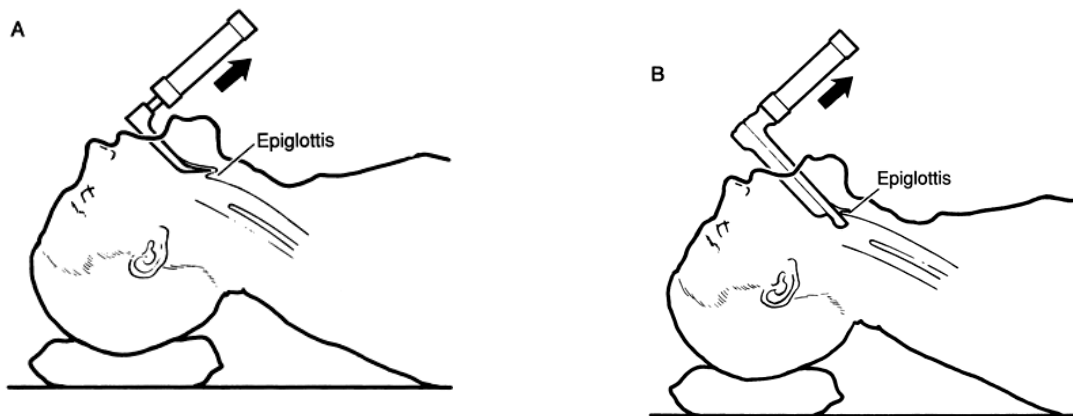
THE LARYNGEAL INLET

The paired vocal cords are the “target” for the laryngoscopist, and are identified by their whitish colour and triangular orientation. Surrounding the vocal cords, the laryngeal inlet is bordered anteriorly by the epiglottis, laterally by the aryepiglottic folds, and inferiorly by the cuneiform and corniculate tubercles (posterior cartilages). Between the posterior cartilages is the **interarytenoid notch**. This landmark is the most posterior and most important aspect of the laryngeal inlet, because in a restricted view situation, it may be the only landmark identifying the entrance to the glottic opening above.

The overlying mucosa on the upper surface of the epiglottis sweeps forward to join the base of the tongue, with prominences forming the median and lateral glossoepiglottic folds. The paired valleys between these folds are called the **valleculae**.



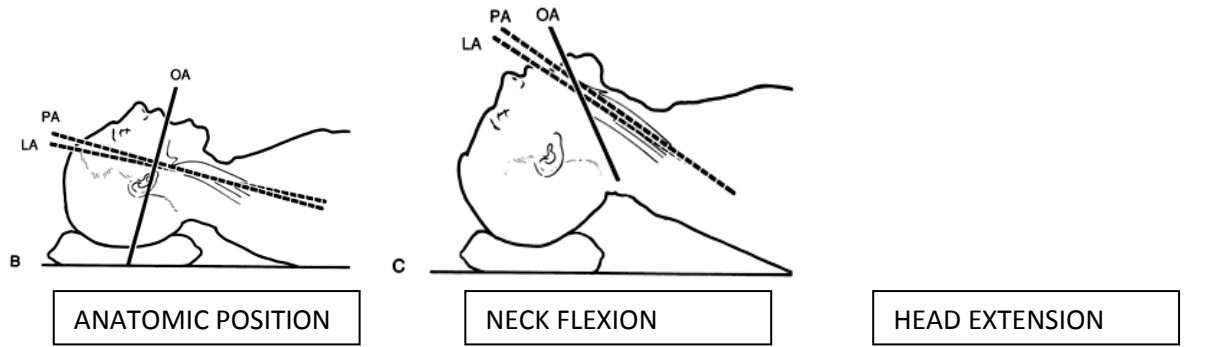
To expose the vocal cords, the tip of a curved (Macintosh) blade can be advanced into the vallecula until it engages the underlying hyoepiglottic ligament. Pressure on this ligament with the blade tip helps evert (“flips up”) the epiglottis to achieve a line-of-sight view into the larynx (Fig.A). Clinicians preferring straight (Miller) blade usually place the blade beneath the epiglottis and directly lift it (Fig.B). Either way, the epiglottis is an important landmark in airway management, and should be a source of reassurance, not anxiety.



AIRWAY AXES:

In the standard anatomic (military) position, the axis of the oral cavity sits at close to right angles to the axes of the pharynx and trachea. To obtain direct visualization during laryngoscopy, this angle needs to be increased to 180°. The pharyngeal and tracheal axes can be aligned by flexion of the lower cervical spine at the cervicothoracic junction, while alignment of the oral and pharyngeal/tracheal axes then occurs with extension at the atlantooccipital junction and upper

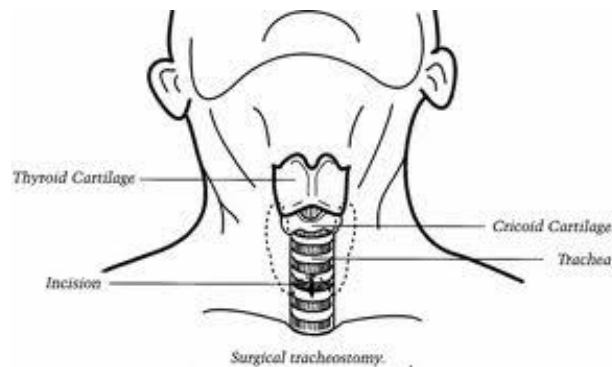
few cervical vertebrae ("sniffing position").



THE LOWER AIRWAY:

The trachea extends from the inferior border of the cricoid cartilage to the level of the T6, where it splits into the left and right mainstem bronchus. The trachea is 12-15 cms long in the average adult and is composed of C-shaped cartilages joined vertically by fibroelastic tissue and completed posteriorly by the vertical trachealis muscle. The anterior tracheal cartilages are responsible for the "clicking" sensation transmitted to a clinician's fingers following advancement of a bougie. The right mainstem bronchus is shorter and more vertical (endobronchial intubation is more common in the right side).

SURGICAL AIRWAY ANATOMY:



One-third of the trachea lies external to the thorax: the first 3-4 tracheal rings lie between the cricoid and the sternal notch. These rings are the common location for elective tracheostomies. Urgent percutaneous access to the trachea is more commonly achieved through the relatively avascular and easily palpable cricothyroid membrane.

AIRWAY INNERVATION:

Knowledge of airway innervation is important to the anaesthetist contemplating application of airway anesthesia to facilitate an "awake" intubation.

- A superior laryngeal nerve block anesthetizes the nerves that supply the epiglottis, aryepiglottic folds, and the laryngeal structures down to the false cords. This can be achieved by injecting 2 ml lidocaine between the greater cornu of the hyoid bone and the thyroid cartilage.
- A glossopharyngeal nerve (GPN) block anesthetizes the posterior tongue. This block can be achieved by injecting 2 mL of lidocaine in the base of the tongue in the area where the tongue opposes the palatoglossal fold.
- A transtracheal block anesthetizes the trachea below the area of the vocal cords. This is done by injecting 2 to 3 mL of lidocaine through the cricothyroid membrane with a 23G needle after confirmation of needle placement in the trachea with aspiration of air.

THE PEDIATRIC AIRWAY:

- The head-to-body size ratio is greater in infants and young children. Optimal airway angulation for laryngoscopy is achieved in infants by placing a towel under the shoulders.
- In infants, the larynx is at C2-3 and migrates in the first 5 years to its adult location at C4-5. This relatively high larynx is described by the laryngoscopist as an anterior larynx.
- Epiglottis is longer, soft and floppy, this necessitates the laryngoscope blade to include the epiglottis for glottic visualization.
- Cuffed ET tubes are not essential below age 5 because the cricoid ring, the narrowest part of the pediatric airway, can form a reasonably tight fit and seal around the ET tube.
- The short trachea often results in right mainstem ET tube placement. The ET tube depth should be $\text{Age}/2 + 12$ (cms).

SUMMARY:

Familiarity with airway anatomy is vital for successful intubation, where landmark recognition is instrumental in leading the clinician to the laryngeal inlet. Equally, to be successful with the use of alternate airway devices, the clinician should possess a 'mental image' of the airway structures through which they pass.

VASCULAR ANATOMY: IT'S IMPORTANCE

INTRODUCTION:

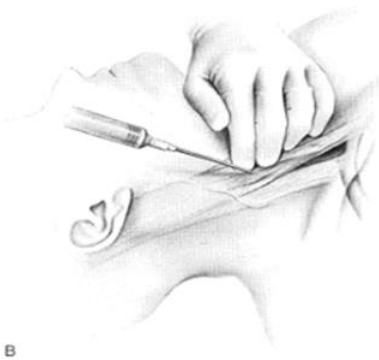Vascular access relies on easily identifiable surface landmarks and predictable anatomic relationships. Knowledge of three-dimensional anatomy relating to the access approaches is imperative for successful cannulation..

INTERNAL JUGULAR VEIN ACCESS

ANATOMY: The internal jugular vein (IJV) is a continuation of the sigmoid sinus as it emerges from the jugular foramen. The vein is invested within the carotid sheath and courses with the vagus nerve and internal and common carotid arteries along its length. Although it exits the skull posterior to the internal carotid artery, the vein assumes a position anterolateral to the common carotid artery as it courses beneath the sternocleidomastoid (SCM). As it reaches the level of the cricoid cartilage, the jugular vein lies just beneath the SCM and emerges between the two heads at the base of the neck. At this site, the vein lies 1 to 1.5 cm from the skin. The IJV joins the subclavian vein to form the brachiocephalic vein behind the medial clavicle.

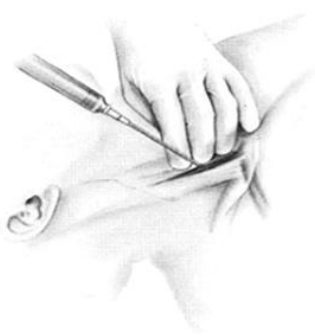TECHNIQUE:

Anterior approach (Fig.B)



The important landmark is the midpoint of the sternal head of the SCM. At this point, the carotid artery can be palpated **1 cm inside the lateral border of the sternal head** and the needle is introduced **0.5 to 1 cm lateral to the pulsation**. The needle should form a 45° angle with the frontal plane and be directed caudally parallel to the carotid artery toward the ipsilateral nipple. Venipuncture occurs within 5 cms.

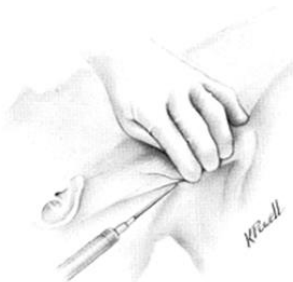Central approach (Fig.C)



C

The apex of the triangle formed by the heads of the SCM marks the needle insertion site. Introduce the seeker needle lateral to the carotid pulsation at an angle 30 to 45 degrees to the skin. Direct the needle lateral to the sagittal plane toward the ipsilateral nipple. Following localization, maintain the position of the seeker needle to serve as a guide for the introducer needle, which is inserted along the same vector.

Posterior approach (Fig.D)



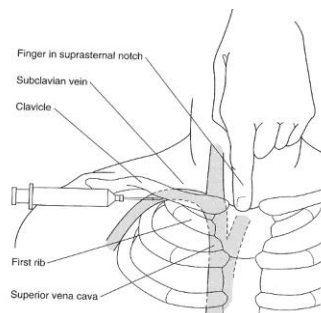
D

The posterior approach uses the external jugular vein (EJV) as a surface landmark. The needle is introduced 1 cm dorsally to the point where the EJV crosses the posterior border of the SCM. The needle is directed caudally towards the suprasternal notch at an angle of 45 degrees to the sagittal plane, with a 15-degree upward angulation. Venipuncture occurs within 4-6 cms.

SUBCLAVIAN VEIN ACCESS

ANATOMY: The subclavian vein is the direct continuation of the axillary vein and begins at the lateral border of the first rib. The vessel arches cephalad behind the medial clavicle and then slopes caudally to join the internal jugular vein to form the brachiocephalic (innominate) vein posterior to the sternoclavicular joint.

TECHNIQUE:



Insert the needle 2 to 3 cms inferior to the midpoint of the clavicle and aim just deep to the suprasternal notch. The clavicle may be initially contacted and then walked deeper to reach the underside of the clavicle. Keep the needle parallel to floor (in the coronal plane) to facilitate sliding beneath the bone and to minimize the risk of pleural puncture. Enter the vein as it passes beneath the junction of the middle and medial thirds of clavicle.

EXTERNAL JUGULAR VEIN ACCESS

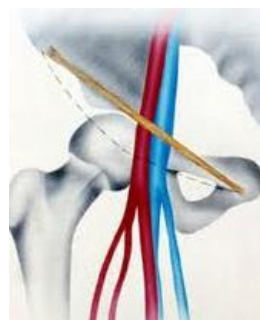ANATOMY: The external jugular vein is a superficial vein of the neck amenable to visual identification. The vessel takes an oblique course across the anterolateral neck (crosses over the SCM at a point one-third of the distance along the line between the sternal head of the clavicle and the mastoid process).

TECHNIQUE: Stabilize the vein with skin traction, and approach the vessel at a 10° angle to the skin.

FEMORAL VEIN ACCESS

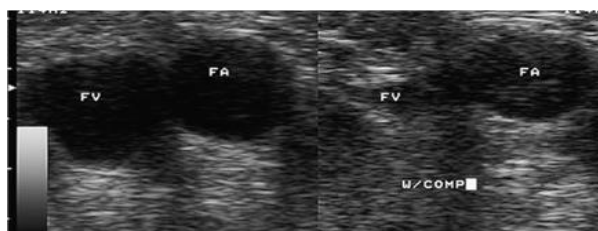ANATOMY: The vessel traverses the thigh and takes a superficial course at the femoral triangle before passing beneath the inguinal ligament and into the pelvis as the external iliac vein. Within the femoral triangle, the femoral vein is enclosed in the femoral sheath where it lies between the lateral femoral artery and medial femoral canal.

TECHNIQUE:



The femoral artery lies at the mid-inguinal point, which lies midway between pubic symphysis and the anterior superior iliac spine. The target venipuncture site is just inferior to the inguinal ligament where the common femoral vein lies superficial and medial to the artery. Orient the needle with the bevel up and introduce it angled 20 to 30 degrees to the skin. Insert the needle 1 to 2 cm inferior to the inguinal ligament and just medial to the femoral artery. The vessel is normally reached within 2 to 4 cm.

USG aided identification of femoral vein showing the compressibility of femoral vein (FV), when compared to femoral artery (FA)



SUMMARY:

Selection of the most appropriate site for venous cannulation is a complex decision based on the operator's experience and individual patient anatomy, risk factors, and access needs. Success rates and complications are clearly influenced by operator experience. Nevertheless, knowledge of different techniques is important to meet variable patient needs.